



## Case report of Mikulicz's disease – a modern concept of an old entity

### Prikaz bolesnika sa Mikuličevom bolesti – savremeni koncept starog entiteta

Ksenija Božić\*, Branislava Glišić\*†, Olga Radić-Tasić‡, Bojana Knežević\*

\*Clinic of Rheumatology, †Institute of Pathology, Military Medical Academy, Belgrade, Serbia; ‡Faculty of Medicine of the Military Medical Academy, University of Defence, Belgrade, Serbia

#### Abstract

**Introduction.** Modern knowledge defines Mikulicz's disease as a part of immunoglobulin G4-related disease. The main feature is the presence of lymphoplasmacytic infiltrates, immunoglobulin G4 plasma cells positivity, distinctive storiform fibrosis and moderate eosinophilia. **Case report.** A 59-years old male presented with a mild keratoconjunctivitis sicca and enlarged lacrimal and salivary glands during the last two years. Although clinical presentation of the patient was typical, earlier testing did not pinpoint Mikulicz's disease. By typical clinical presentation, elevated serum immunoglobulin G4 level and histopathological finding of lacrimal glands tissue we diagnosed Mikulicz's disease successfully treated with corticosteroid therapy. **Conclusion.** We reported the first case of IgG4-related Mikulicz's disease in Serbia. Our report highlights IgG4-related Mikulicz's disease as an important differential diagnosis with Sjögren's syndrome and lymphoproliferative disease in rheumatological practice.

#### Key words:

mikulicz' disease; diagnosis, differential; diagnosis; lacrimal apparatus; salivary glands; immunoglobulin G; histological techniques; glucocorticoids; treatment outcome.

#### Apstrakt

**Uvod.** Savremena saznanja svrstala su Mikuličevu bolest u grupu bolesti posredovanih imunoglobulinom G4, čija je glavna odlika histološki nalaz limfoplazmocitnih infiltrata, imunoglobulin G4 pozitivnih plazma ćelija, uz storiformnu fibrozu i umerenu eozinofiliju. **Prikaz bolesnika.** Prikazan je 59-godišnji bolesnik koji je dve godine imao umeren suvi keratokonjuktivitis i uvećane pljuvačne i suzne žlezde. Iako je klinička slika bila karakteristična, ranijim ispitivanjem nije se došlo do dijagnoze Mikuličeve bolesti. Na osnovu tipičnog kliničkog nalaza, visoke serumske koncentracije imunoglobulina G4, uz patohistološki nalaz biopsije tkiva suznih žlezda, dijagnostikovali smo Mikuličevu bolest. Primenjena terapija kortikosteroidima bila je efikasna. **Zaključak.** Prikazali smo prvog bolesnika u Srbiji sa Mikuličevom bolesti posredovanim imunoglobulinom G4. Našim prikazom istakli smo značaj poznavanja Mikuličeve bolesti posredovane IgG4, kao i diferencijalnu dijagnozu sa Sjögrenovim sindromom i limfoproliferativnim bolestima u reumatološkoj praksi.

#### Ključne reči:

mikuličeva bolest; dijagnoza, diferencijalna; dijagnoza; suzni aparat; pljuvačne žlezde; IGG; histološke tehnike; glukokortikoidi; lečenje, ishod.

#### Introduction

Immunoglobulin G4 (IgG4)-related diseases (IgG4-RD) are new clinical entity of fibro-inflammatory conditions, characterized by the tendency to form tumorous lesions, dense lymphoplasmacytic infiltration abundant of IgG4-positive plasma cells and storiform fibrosis in relevant organs and often, but not always, elevated serum IgG4 levels<sup>1</sup>. The concept is based on the discovery of increased serum IgG4 levels in patients with sclerosing pancreatitis<sup>2</sup>. IgG4-RD can affect various organs, pancreas more often than the others as well as hepatobiliary tract, salivary and lacrimal glands, orbits and lymph nodes.

Very little data exists on the incidence and prevalence of IgG4-RD. Most epidemiological studies come from Japan and they are focused on autoimmune pancreatitis. It was estimated that the incidence of new cases with IgG4-RD is 2.63–10.2/million, with newly diagnosed 336–1,300 patients per year<sup>3</sup>.

Mikulicz's disease (MD) is characterized by symmetrical, painless enlargement of lacrimal, parotid and submandibular salivary glands. Based on histological similarities, this disease was considered for a long time as a subtype of Sjögren's syndrome (SS). A recent research of Japanese authors has discovered increased serum IgG4 levels in pati-

ents with MD and defined histopathological findings in glands tissue, presenting MD as part of IgG4-RD<sup>4</sup>.

Today, the focus of interest is how to differentiate the diagnosis of MD and SS. MD is usually observed in patients older than 50 years, both males and females. In spite of the persistent swelling of salivary and lacrimal glands, their function is not significantly reduced. The number of positive antinuclear antibody (ANA) is small, while anti-Ro and anti-La antibodies are negative. Patients with SS are mostly females around 50 years old. Although gland swellings in SS are intermittent, *keratoconjunctivitis sicca* is present. Serum tests in most patients show positive ANA, 70% of them have anti-Ro and 30% anti-La antibodies. High serum level of IgG4 is specific for MD, but is usually not seen in SS. The basics for MD diagnosing is a histopathological feature. Although the lymphocytic infiltrates are typical for MD and SS, their influence is different. In MD lymphoid follicles are placed around the duct protecting it while in SS they create lymphoepithelial lesions and destroy the duct. This explains less frequent *keratoconjunctivitis sicca* in MD in spite of significant gland swellings. Infiltration of IgG4 positive plasma cells is the main difference between MD and SS. The ratio of IgG4 positive cells to IgG positive cells is higher than 40%. Steroid therapy is efficient in MD, but partially in SS. In spite of certain clinical similarities, MD and SS are two different diseases<sup>5,6</sup>.

We presented the first patient with proven IgG4-related MD in our country.

### Case report

A 59-year-old man was admitted to our hospital due to chronic dacryoadenitis and sialadenitis, with suspicion of the

existence of lymphoproliferative disease. The patient had dry mouth and painless swelling in the area of parotid salivary glands during two years. A year before hospitalization he noticed swollen eyelids. His other problem was nasal obstruction. The diagnosis of *keratoconjunctivitis sicca* was made in other hospital a year before. There was no evidence for the existence of SS (Schirmer's test was 7 and 8 mm; scintigraphy showed mildly reduced accumulative and excretory function of salivary glands; ANA, anti-Ro and anti-La antibodies were negative; ultrasound showed enlarged parotid and submandibular salivary glands; biopsy of the minor labial salivary gland was negative). The computed tomography (CT) scan showed enlarged lacrimal glands more on the left side (Figure 1). Biopsy of the both glands was performed. The results showed chronic dacryoadenitis followed by significant polyclonal proliferation of the plasma cells. Lymphoproliferative disease was suspected.

On admission the patient was obese, body mass index (BMI) of 34 kg/m<sup>2</sup> (normal range 18.5–25 kg/m<sup>2</sup>), with enlarged, painless parotid, submandibular and lacrimal glands (Figure 2).

Blood tests showed erythrocytes sedimentation rate (SER) of 70 mm/h (the normal range is 0–22 mm/h form men), C-reactive protein (CRP) of 7.61 mg/L (normal range: less than 10 mg/L), polyclonal hipergamaglobulinemia IgG of 28.3 g/L (normal range: 5–16 g/L) and IgE of 1,060 UI/mL. Serological markers including ANA, anti-Ro, anti-La and RF were negative. The serum IgG4 level was 15.7 g/L (normal range: 0–1.3 g/L). Inflammatory pseudotumor of the lacrimal gland with signs of storiform fibrosis revealed after histopathological and immunohistological analysis. The IgG4 positive plasma cells infiltration was enormous, once microscopically enlarged where ratio IgG4+/ IgG+ was at le-

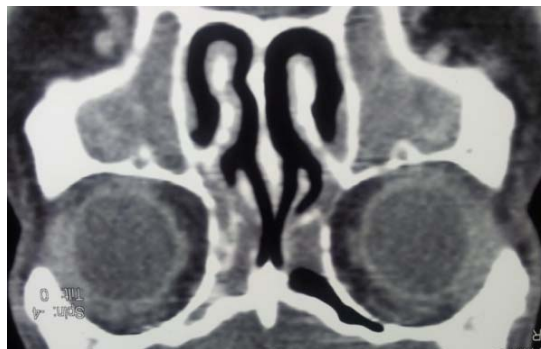
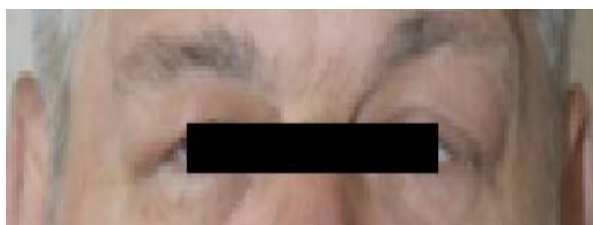
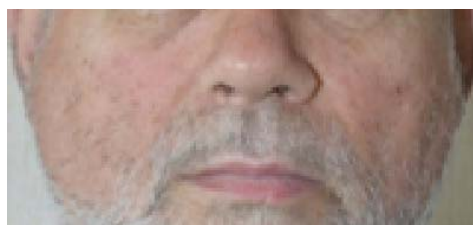

Fig. 1 – Computed tomography (CT) images reveal enlargement of the lacrimal glands.



A



B

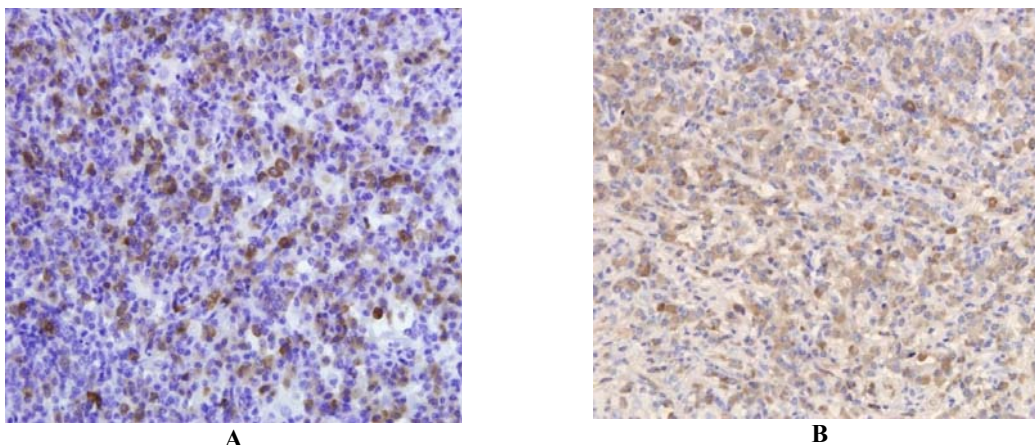
Fig. 2 – A) Dacryoadenitis manifests as bilateral swelling of upper eyelids, and B) Sialadenitis manifests as bilateral swelling of parotid regions in the same patient.

ast 40% (Figure 3). There was no histological criteria for a lymphoproliferative neoplasm.

Additional tests were done including myelogram and analysis of clonality in bone marrow lymphocytes. Using polymerase chain reaction method, no lymphoproliferative disease was found.

On the seventh hospital day, the patient showed signs of compressive, peripheral paresis of the left facial nerve. It was the reason for urgent corticosteroid therapy with prednisone 0.5 mg/kg/day. Two weeks later, swelling disappeared completely and the facial nerve recovered its function. The

tic criteria for IgG4-related MD. According to them, IgG4-related MD defines with persistent (longer than 3 months) symmetrical swellings of at least 2 pairs of lacrimal, parotid or submandibular glands, elevated serum IgG4 levels (> 135 mg/dL) or histopathologically marked infiltration of IgG4 positive plasma cells with a ratio of IgG4 /IgG > 40%, with typical tissue fibrosis or sclerosis<sup>13</sup>. So, patients with swelling of salivary and lacrimal glands, elevated serum IgG4 levels and significant infiltration of IgG4 positive plasma cells in lacrimal gland tissue fulfil all the criteria for IgG4-related MD.



**Fig. 3 – Histological findings of lacrimal gland biopsies. Immunohistochemical staining showing: A) IgG4-positive plasma cells, and B) IgG-positive plasma cells in the lacrimal gland section of the patient (x200).**

corticosteroid dosage was tapering gradually 2.5 mg *per* week. After a 3-month follow-up, the patient was still without any complaints. He continued to receive prednisolone 10 mg *per* day as maintenance therapy.

### Discussion

By the end of the 19th century, Johan von Mikulicz-Radecki described a patient with symmetrical swellings of the lacrimal, submandibular and parotid glands with massive infiltration of the glands by mononuclear cells<sup>7</sup>. Later, these clinical features were observed in patients with tuberculosis, sarcoidosis and lymphomas<sup>8</sup>. Schafer and Jacobsen<sup>9</sup> formed a group of patients with typical clinical features known as Mikulicz's syndrome. In 1933, Henrik Sjögren<sup>10</sup> described histopathological lymphocyte infiltrates in salivary gland of patients with *keratoconjunctivitis sicca* and swollen main salivary glands. But his findings were forgotten until the mid 20th century, when Morgan and Castelman observed that salivary glands tissues in MD and SS are similar<sup>11</sup>. Since then, MD is considered as a subtype of SS chronic form of dacryoadenitis and sialadenitis of an autoimmune etiology<sup>11</sup>.

The research of Japanese authors in the 21st century shows elevated serum IgG4 levels and histopathologically abundant infiltration of IgG4 positive plasma cells in lacrimal and salivary glands of patients with MD. This is the creation of a modern clinical concept clearly differentiating MD from SS, putting MD to the group of IgG4-RD<sup>12</sup>. The Japanese Society for Sjögren's Syndrome has published diagnos-

The clonality of lymphocytes is necessary to be tested due to histopathological similarities between IgG4-related MD and lymphoma. In the early diagnosing of B-cell lymphomas, they are predominantly represented by B-cell infiltrates unlike primary T-cell infiltrates in IgG4-RD<sup>14</sup>.

Allergic rhinitis and bronchial asthma are more frequent in MD than in SS. A high occurrence of allergic conditions is explained by domination of type 2 helper T (Th2) cells immune response, which raises the concentration of IgG4 and IgE<sup>15</sup>.

Corticosteroids are the standard first-line treatment for IgG4-related MD. They rapidly reduce swellings of lacrimal and salivary glands, recover their functions and reduce IgG4 concentration in serum<sup>16</sup>.

A number of patients with IgG4-related MD was described in Japan with just a few individual cases in the western world. In spite of low prevalence of IgG4-related MD, it is necessary to have it in mind when dealing with patients presenting with swollen lacrimal and salivary glands.

### Conclusion

In suspicion for Mikulicz's disease serum levels of immunoglobulin G4 as well as biopsies from glands with immunohistochemical evaluation should be assessed. It is necessary to distinguish immunoglobulin G4-related Mikulicz's disease from other distinct disorders, including Sjögren's syndrome and lymphoproliferative disease. Therapy with corticosteroids is efficient and recommended for a longer period of time.

## R E F E R E N C E S

1. *Khosroshahi A, Stone JH.* A clinical overview of IgG4-related systemic disease. *Curr Opin Rheumatol* 2011; 23(1): 57–66.
2. *Hamano H, Kawa S, Horiuchi A, Unno H, Furuya N, Akamatsu T,* et al. High serum IgG4 concentrations in patients with sclerosing pancreatitis. *N Engl J Med* 2001; 344(10): 732–8.
3. *Hamano H, Arakura N, Muraki T, Ozaki Y, Kiyosawa K, Kawa S.* Prevalence and distribution of extrapancreatic lesions complicating autoimmune pancreatitis. *J Gastroenterol* 2006; 41(12): 1197–205.
4. *Yamamoto M, Takabashi H, Sugai S, Imai K.* Clinical and pathological characteristics of Mikulicz's disease (IgG4-related plasmacytic exocrinopathy). *Autoimmun Rev* 2005; 4(4): 195–200.
5. *Guma M, Firestein GS.* Best Practice. *Res Clin Rheumatol* 2012; 26(4): 425–38.
6. *Yamamoto M, Takabashi H, Obara M, Suzuki C, Naishiro Y, Yamamoto H,* et al. A new conceptualization for Mikulicz's disease as an IgG4-related plasmacytic disease. *Mod Rheumatol* 2006; 16(6): 335–40.
7. *Mikulicz JH.* Über eine eigenartige symmetrische Erkrankung der Tränen- und Mundspeicheldrüsen. Stuttgart: Beitr Chir Fortschr; 1892.
8. *Napp O.* Über die Beziehungen der Mikulicz'schen Erkrankung Tuberkulose. *Stschr Augenheilk* 1907; 17: 513.
9. *Schaffer AJ, Jacobsen AW.* Mikulicz's syndrome: a report of ten cases. *Am J Dis Child* 1927; 34(3): 327–46.
10. *Sjögren HS.* Zur kenntnis der keratoconjunctivitis sicca (Keratitis follicularis bei hypofunktion der tranendrüsen). *Acta Ophthalmol (Copenh)* 1933; 2: 1–151.
11. *Morgan WS.* The probable systemic nature of Mikulicz's disease and its relation to Sjögren's syndrome. *N Engl J Med* 1954; 251(1): 5–10.
12. *Umebara H, Okazaki K, Masaki Y, Kawano M, Yamamoto M, Saeki T,* et al. A novel clinical entity, IgG4-related disease (IgG4RD): general concept and details. *Mod Rheumatol* 2012; 22(1): 1–14.
13. *Umebara H, Okazaki K, Masaki Y, Kawano M, Yamamoto M, Saeki T,* et al. Comprehensive diagnostic criteria for IgG4-related disease (IgG4-RD), 2011. *Mod Rheumatol* 2012; 22(1): 21–30.
14. *Stone JH, Zen Y, Deshpande V.* IgG4-related disease. *N Engl J Med* 2012; 366(6): 539–51.
15. *Masaki Y, Dong L, Kurose N, Kitagawa K, Morikawa Y, Yamamoto M,* et al. Proposal for a new clinical entity, IgG4-positive multiorgan lymphoproliferative syndrome: analysis of 64 cases of IgG4-related disorders. *Ann Rheum Dis* 2009; 68(8): 1310–5.
16. *Khosroshahi A, Stone JH.* Treatment approaches to IgG4-related systemic disease. *Curr Opin Rheumatol* 2011; 23(1): 67–71.

Received on January 18, 2015.  
Revised on February 24, 2015.  
Accepted on February 27, 2015.  
Online First October, 2015.